
The Podiatrists Nightmare
Michael O' Neill
Consultant Podiatrist
Podiatric Surgeon
Bart' s Health NHS
Trust


Plantar Fasciitis
Its been hurting for 6 months
I' ve tried insoles
Changed my shoes
Swallowing tablets
Rub in cream
Then you notice
Flat Ballet pump shoes
3 Stone over weight!
18 % of NP =Heel Pain
67 % Working Diagnostics =PF


Plantar Fasciitis
Inflammatory process of the plantar fascia and /or periostitis of the calcaneum usually secondary to excessive pronatory forces,often in overweight individuals and presents with post static dyskinesia,especially on arising in morning with pin point pain noted at the medial plantar aspect of the calcaneum

Where it Hurts

- Pain Usually plantar anterio-calcaneal
- sometimes into arch
- Sometimes lateral foot
- Pain, mild or debilitating, chronic or acute
- Usually Unilateral

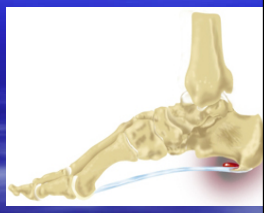

When it Hurts

- First step pain in morning.
- Post static dyskinesia
- Feels like a pulling sensation when walking.
- Worse barefoot or wearing a low-heeled or unsupportive shoe.
- After exercise or standing
- Shopping (especially for men)
- Conference walking

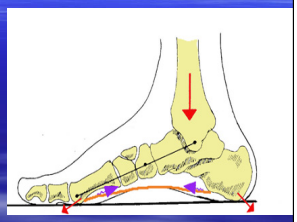

Who it hurts

- 2:1 F/M
- 70% within 30-50 Age group
- CHANGE OFSOMETHING ACTIVITY /HOLIDAYS / SPORTS/ CHILDBIRTH / WEIGHT / SHOES
- COMPRAMISED MECHANICS
- XS Pronator.
- Post or pre Sx eg, TKR

Anatomy of the Plantar Fascia

- Broad, dense band of longitudinally arranged collagen fibers
- 3 bands: medial, central, lateral
- Origin: anterior aspect of calcaneal tuberosity
- Distally divides into 5 digital bands at the metatarsophalangeal joints
- Each digital band pass on either side of flexor tendons and inserts dorsally at the base of the toes.

Anatomy

- Plantar Fascia
  - A fibrous band
  - Supports the arch

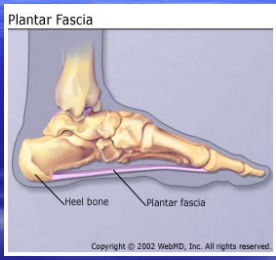

Anatomy of Medial Ankle

- Posterior Tibial Nerve
  - Supplies bottom of foot and heel.
- Flexor Retinaculum
  - Supports Tendons, Arteries, and Nerves
- Nerve compression may occur.

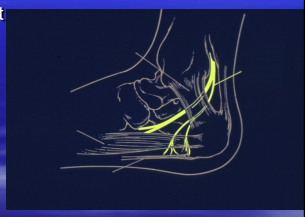

Why it hurts

- Degenerative changes from repetitive micro-trauma at origin of plantar fascia cause traction periostitis and micro-tears resulting in pain and inflammation.
- As the foot flattens there is a stretch on the ligament that supports the foot and arch causing inflammation and tearing

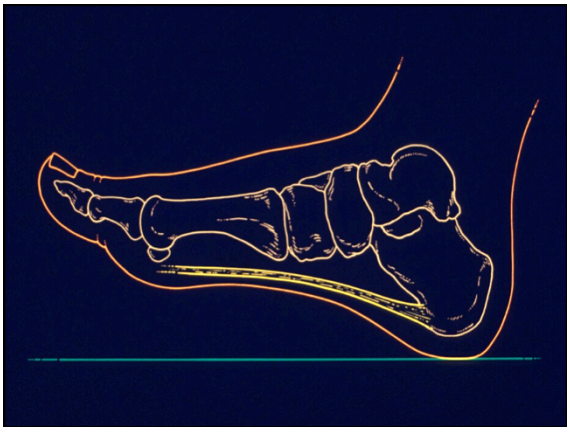

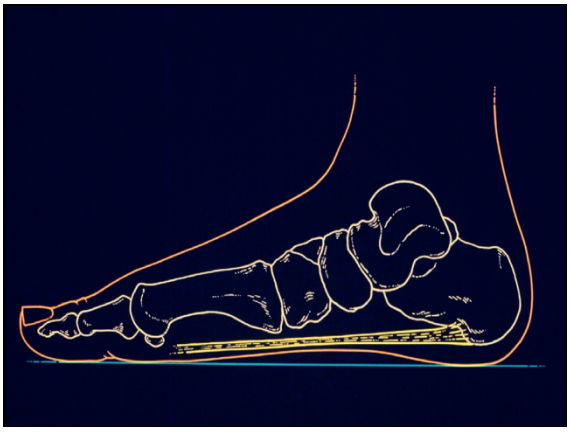

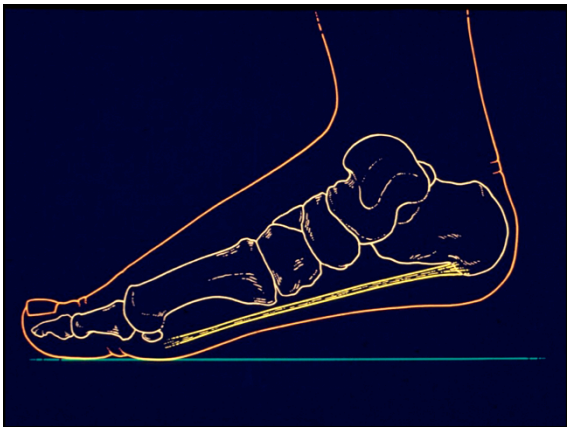

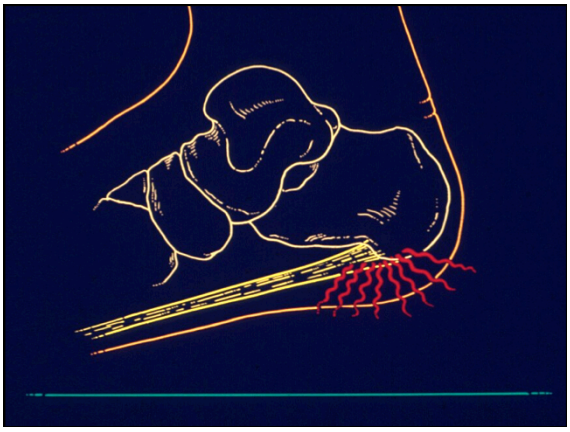

Differential Diagnoses

- plantar fasciitis
- inflammation of tendon or bursa
- heel bruise
- systemic disease such as rheumatoid arthritis
- nerve entrapment
- heel bone stress fracture
- tumor
- plantar fascia rupture
- soft tissue infection
- bone infection
- neuritis
- fat pad syndrome
- infracalcaneal bursitis
- LOW BACK Neural

Other Heel Pain

- Haglunds Deformity
- Retro-calcaneal Bursitis
- Posterior entrapment syndrome
- Severs Disease Normally found in Teenagers

Evaluation

- Majority-pain upon palpation of the medial tubercle of the calcanium
- Palpatory tenderness extends into the medial arch
- Pain may be elicited by extension of foot

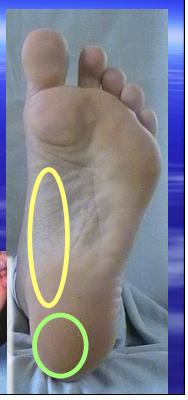

Diagnostics on Clinical presentation only or XR?

- Unilateral
- Typical morning pain resolving after 10-15 minutes, again after rest
- Gradual onset
- No co-morbities
- Activity Change
- Biomechanical Evaluation (Foot / Ankle/Leg/Back)
- XR = Heel Spur : So What

Heel Spurs

- Chronic strain on plantar fascia at attachment to heel bone, creates small tears -> causing new bone formation="heel spur".
- Heel spur="fishhook-shaped structure"
- Pain often due to inflammation not spur.

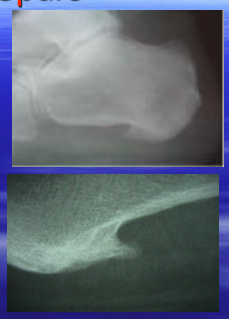

Significance of Heel Spurs

•Not considered the cause.

•Present in approx. 50% of patients with plantar fasciitis.

•Probably caused by chronic inflammation.

•Repetitive traction-trauma at the origin of the fascia and the flexor digitorum brevis muscle.

•**HEEL SPURS CAN FRACTURE!!**

Significance of Heel Spurs

Shmokler et al, 1988:

13.2% incidence of heel spurs in 1000 randomly chosen patients;

5.2% of the total of patients with heel spurs did not report any history of heel pain.

Treatment of MSK Problem

- Co morbitiy management
- Biomechanical Management to Address
  - repetitive pull or strain on soft tissue attachments
  - foot type (low or high arch)
  - obesity
  - inappropriate shoe gear
  - unyielding surfaces
  - extensive activity
  - varus/valgus foot type

Treatment of MSK Problem

- Footwear
- Strapping
- Orthotics
- Stretching TA PF HS
- Activity Modification
- Ice / Massage
- Night Splint after 6/52 if no improvement in morning pain
- NSAID
- Laser
- Ultrasound
- Acupuncture
- Homeopathy

Night Splints for PF

- Posterior night splints
  - passively stretches calf, plantar fascia, and Achilles tendon while sleeping
  - decreases AM tension
  - Disadvantages:
    - possible mild discomfort
    - possible sleep interruption

3/12 What to expect

- First pain to reduce is the morning pain.
- If VAS pain is 50% Continue with treatment plan
- No Change in symptoms or
- Morning pain ISQ
- Less than 25% Improvement
- Review Pt Compliance
- Review Diagnostics
- Start Tests/ Investigations

6/12 What to expect

- Morning Pain mostly gone.
- If VAS pain is 25% Continue with treatment plan
- Pt STILL IN PAIN and
- FED UP- Blames You
- Review All Results
- Excluded other Local and systemic causes.
- When do you inject
- What else can you do
- 2nd opinion
- Pain Management

Further Studies WHEN?

Suspect other problems or Failure to respond to treatment

- MRI
- Ultrasound
- Bone Scan
- EMG
- Bloods (ESR, serum urate, rheumatoid panel, etc.)

Steroid injection

X Ray Before inject
Ultrasound Guided if available

Corticosteroid injections

- 95% improve initially
- Maximum benefit last for 6-8 weeks
- < 50 % has long term benefit

Bordelon; ***CORR*** 177,1983 p 49-53

Corticosteroid injections

- Not more than two injections
- Plantar fascia rupture
- Fat pad necrosis
- When ?
- Approach?
  - Medial or plantar

Sellman JR, *Foot Ankle* 1994, 15: 376-81

Ultrasound guided corticosteroid injection for plantar fasciitis: randomised controlled

trialBMJ 2012; 344 doi: http://dx.doi.org/10.1136/bmj.e3260 (Published 22 May 2012)Cite this as: BMJ 2012;344:e3260

What this study adds

A single ultrasound guided dexamethasone injection is a safe and effective short term treatment for plantar fasciitislt

provides significantly greater pain relief than placebo at four weeks,

Reduces abnormal swelling of the plantar fascia for up to three months

Significant pain relief did not, however, continue beyond four weeks

Acupuncture

Helps to relax connective tissue

Decrease irritation

Stimulates the body to produce endorphins

This moderates pain as healing accelerates

Surgical Treatments

- reserved only for patients not responding to conservative therapy
- involves cutting of plantar fascia and possible removal of heel bone spur
- Open or Endoscopic

Open Heel Surgery

- Medial incision
- Release plantar fascia at heel spur
- Resect heel spur
- Longer recovery

Surgical management

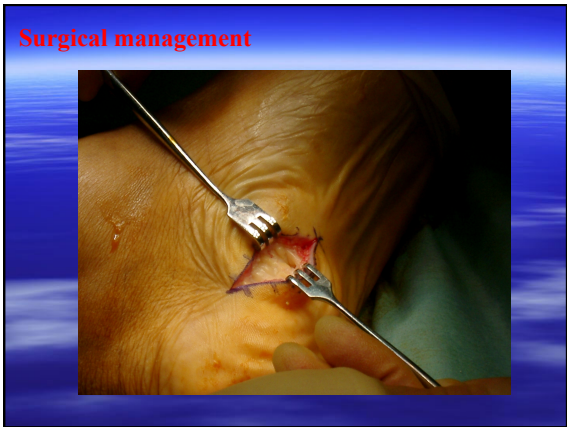
Surgical management


Surgical management


Surgical management

Endoscopic Plantar Fasciotomy



- Closed approach through small incision
- Cutting medial 1/3 to 1/2 of fibrous band
- Advantages: less trauma, less postop pain, quicker recovery, and can bear weight

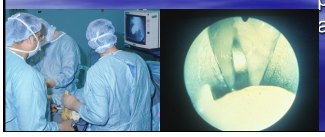

Extracorporal Shock Therapy Indications

Indicated for heel pain over 6 months

Unresolved with conservative therapy

ECSWT / Lithotripsy Uses

The energy flow density is differentiated according to the given application

APPLICATIONS

Pain Management

Tissue Destruction

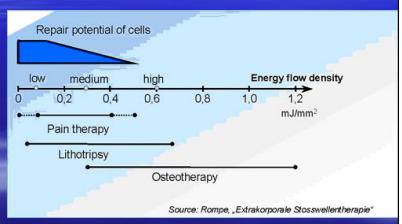

Extracorporal Shock Therapy

The Mechanics

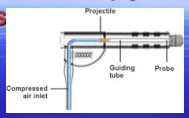

(ESWT) Utilises a Ballistic Technique.

A projectile, accelerated by compressed air ,propelled at high kinetic energy, hits an applicator placed on the skin.

This impulse is delivered to the tissue in the form of a shock wave.

From this point the shock wave continues to spread inside the body in the form of a "radial" wave.

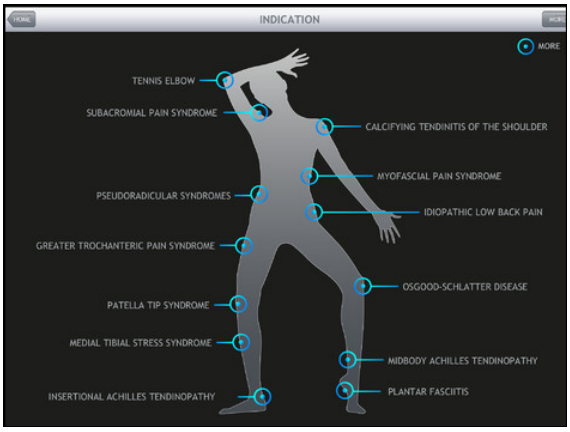

Extracorporal Shock Therapy

Initiates an inflammation-like condition in the tissue that is being treated.

The body responds by increasing the blood circulation and metabolism in the impact area

This in turn accelerates the body's own healing processes.

The shockwaves break down injured tissue and calcifications.

Extracorporal Shock Therapy

Advantages
for the Patient
Compared to Sx

Outpatient treatment
No time off work
Significant reduction in pain
Reported 80% Success rate
Faster return to normal activity

Advantages
For the Clinician
Compared to Sx

Broad range of applications
High patient acceptance
Simple procedure
fewer potential complications



Extracorporal Shock Therapy Contraindications

- No cortisone injections 6/52 prior to treatment
- Coagulation Problems
- Cardiac Pacemaker
- Ischemia
- Acute inflammation in the treatment area
- Cancer
- Pregnancy



Extracorporal Shock Therapy

•Usually 3 Treatments
•Patients often in Pain

•No NSAIDS

•Sometimes wont come back for treatment

•NICE Still Evaluating

•Does it work or not?
•The Debate Continues!!

Cryosurgery for Heel Pain

Cryosurgery is the specialized field of using extremely low temperatures

(controlled by a handheld probe)

To destroy pathological tissue.

Cryosurgery for Heel Pain

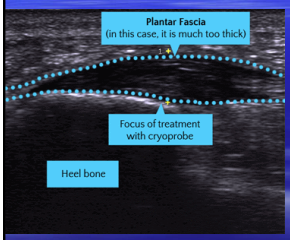

Nerve block applied at the ankle level to numb the heel.

The cryoprobe is guided to the origin of the plantar fascia and 2 x 3 minutes of treatment is applied.

No sutures are required due to the small nature of the incision

Dressings are removed after 48 hours.

Cryosurgery for Heel Pain

Cryosurgery works in several ways.

Firstly it causes desensitisation of nerves in the area of pain without destroying the nerve.

Secondly it triggers an inflammatory response which aids healing.

Calcaneal Nerve entrapments

f any of the following suspect calcaneal
euritis
ntermittent Burning
Pulling Pain
Calcaneal Nerve stretch test +ve
Tinels sign +ve

Cryosurgery for Heel Pain

According to Marc Katz DPM

Reports that freezing of localized points of tenderness and pain in the heel is not the best use of cryosurgery.

Produces indiscriminate damage to tissues,
The nerve causing the painful stimulus should be located proximal to the painful site to ablate all branches of the nerve leading to the area.

Cryosurgery for Heel Pain

According to Marc Katz DPM

Limited to those with Combined Symptoms of PF and Nerve Entrapments
Most often Medial Calcaneal Nerve
Less often Lateral Calcaneal nerve
Lateral calcaneal nerve has motor functions
Therefore surgical release indicated
Freezing Fascia will also risk rupture

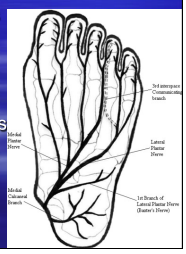

Cryosurgery for Heel Pain Entrapment Technique

- Palpation of the medial calcaneal nerve branch at the medial heel. Following diagnostic injection of 0.5 ml of lignocaine
- cryosurgery of the medial calcaneal nerve
- 3 x 30 second applications with LN Probe
- Full rehab as for PF

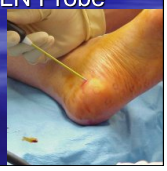

Topaz Coblation for Heel Pain

Minimally invasive medical technique now available for the treatment of tendons and fascia.

5 million Coblation procedures have been performed

Through a small incision, the TOPAZ Micro Debrider is applied for half-second duration Treatments placed a quarter inch apart to form a grid-like pattern

With every fourth application, the device is inserted deeper into the tendon

Small amounts of tissue are removed

Topaz Coblation for Heel Pain Patient Selection

Fascia with partial tears may be at an increased risk of rupture

No acute trauma

No neurogenic disease

No ligamentous disruption, bone and joint abnormalities

Preoperative MRI or US advised.

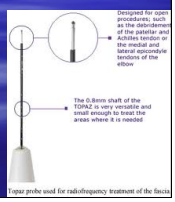

Topaz Coblation for Heel Pain Post operative care

First 3 weeks-use crutches

Immobilize with splint

Week 4-Week 8 Passive and active range of motion exercises

Night splint if appropriate2-3 months

No sports or heavy lifting

Normal routine at home or work is ok

Topaz Coblation for Heel Pain Post operative care

There have been no long term studies to show its effectiveness in plantar fasciitis.

AUDIT ?

Platelet-Rich-Plasma

The concept is that there is a loss of inflammatory response and chronic scar formation with fascia and tendon injuries

With chronic injuries such as Achilles tendinosis and PF, cortisone injections do not help very much.
There is no inflammatory process with these injuries and the injection only works via the trauma caused by the needle,
Resulting in an inflammatory response in the designated area.

Platelet-Rich-Plasma

Alternatively,
PRP injections are very useful in chronic injury cases
They restart and stimulate the inflammatory cascade
Thich enhances the healing process.

Plasma is a liquid component of blood that is mainly water but also includes fibrinogen.
Fibrinogen catches platelets, which are responsible for hemostasis, construction of connective tissue and revascularization.

The alpha granules in platelets contain clotting and growth factors, which are released as part of the growth factors associated with PRP injections.
In turn, this leads to growth factors associated with the inflammatory cascade and healing process.[5]

Platelet-Rich-Plasma

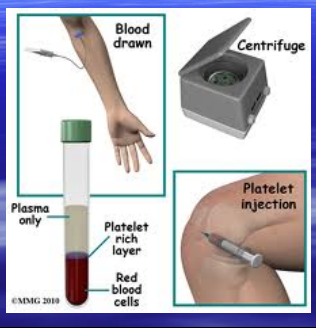

TREAT THE PATIENT NOT JUST THE FOOT

80-95% of patients treated successfully with conservative treatment

fixmyfoot.co.uk


This Heel pain has been hurting me for almost a year
You think they can do better in 400 years ?
Doing the best I can mate. This isn't exactly the 21st Century
Doctor treating a patient in his surgery: 17th Century, after Teniers the younger
FIXMYFOOT.Co.UK


Thank You
Dave Couzins
Michael O'Neill
&
All The Staff @
Thames Valley
Spire Hospital